



**HAL**  
open science

## Bleeding complications following peripheral regional anaesthesia in patients treated with anticoagulants or antiplatelet agents: A systematic review

F. Joubert, P. Gillois, H. Bouaziz, E. Marret, G. Iohom, P. Albaladejo

### ► To cite this version:

F. Joubert, P. Gillois, H. Bouaziz, E. Marret, G. Iohom, et al.. Bleeding complications following peripheral regional anaesthesia in patients treated with anticoagulants or antiplatelet agents: A systematic review. *Anaesthesia Critical Care & Pain Medicine*, 2018. hal-02007730

**HAL Id: hal-02007730**

**<https://hal.univ-grenoble-alpes.fr/hal-02007730>**

Submitted on 20 Jul 2022

**HAL** is a multi-disciplinary open access archive for the deposit and dissemination of scientific research documents, whether they are published or not. The documents may come from teaching and research institutions in France or abroad, or from public or private research centers.

L'archive ouverte pluridisciplinaire **HAL**, est destinée au dépôt et à la diffusion de documents scientifiques de niveau recherche, publiés ou non, émanant des établissements d'enseignement et de recherche français ou étrangers, des laboratoires publics ou privés.



Distributed under a Creative Commons Attribution - NonCommercial 4.0 International License

# **Bleeding complications following peripheral regional anaesthesia in patients treated with anticoagulants or antiplatelet agents: a systematic review**

Joubert F, MD<sup>1</sup>; Gillois P, MD, PhD<sup>2</sup>; Bouaziz H, MD, PhD<sup>3</sup>; Marret E, MD, PhD<sup>4</sup>; Iohom G, MD, PhD<sup>5</sup>, Albaladejo P, MD, PhD<sup>6</sup>

## **Corresponding author:**

Professor Pierre ALBALADEJO

Department of anaesthesiology and intensive care , Grenoble Alpes University Hospital

CHUGA, CS10217, 38043 Grenoble cedex 09- France

palbaladejo@chu-grenoble.fr

## **Affiliations:**

<sup>1</sup> Department of anaesthesiology and intensive care , Grenoble Alpes University Hospital

fjoubert@chu-grenoble.fr

<sup>2</sup> Department of Public Health, Grenoble Alpes University Hospital

pgillois@chu-grenoble.fr

<sup>3</sup> Department of anaesthesiology and intensive care, University of Lorraine – CHU Nancy

h.bouaziz@chu-nancy.fr

<sup>4</sup> Department of anaesthesiology and intensive care, APHP - University of Paris Sorbonne

drmarret@gmail.com

<sup>5</sup> Department of Anaesthesia and Intensive Care Medicine, Cork University Hospital, Cork, Ireland

giohom@ucc.ie

<sup>6</sup> Department of anaesthesiology and intensive care , Grenoble Alpes University Hospital

palbaladejo@chu-grenoble.fr

## Abstract

**Background:** Patients on either antiplatelet or anticoagulant therapy may need procedures performed under peripheral nerve blocks in preference to general anaesthesia techniques. The risk of bleeding associated with peripheral nerve blocks under these circumstances remains unknown. This systematic review evaluates the incidence of bleeding complications following peripheral nerve blocks in patients receiving antiplatelet and/or anticoagulant medication.

**Method:** All English, French and Spanish publications on peripheral nerve blocks in patients receiving antiplatelet and/or anticoagulant medication, from 1978 to 2018 from various sources including Pubmed, were reviewed. Publications on neuraxial anaesthesia (spinal or epidural) and eye blocks were excluded.

**Results:** Twenty-four articles were selected, including six observational studies and 18 case reports. Patients received antiplatelet agents only, in 4 studies, anticoagulants only in 14 studies, and both in 6 studies. In the observational studies, 80 bleeding complications (haematoma or minor bleeding at the puncture site) were identified following 9.738 peripheral nerve blocks. Amongst case reports, 15 bleeding complications were noted following 50 peripheral nerve blocks. Bleeding complications were reported mostly with lumbar plexus blocks (1 requirement for blood transfusion, 1 catheter embolization, 1 surgical exploration and 1 death). The overall estimate of the incidence of bleeding complications was 0.82% (0.64%-1.0%).

**Conclusion:** This systematic review found that bleeding complications following peripheral nerve blocks were rare in patients receiving antiplatelet and/or anticoagulant medication.

*Keywords: nerve block ; anticoagulant ; antiplatelet agent; platelet aggregation inhibitors ; haemorrhagic complications.*

## **Introduction**

Single-shot and continuous peripheral nerve blocks are widely used in clinical practice. Evidence shows that in certain circumstances these techniques may be preferable over general anaesthesia due to the excellent postoperative analgesia afforded, and a lesser incidence of postoperative complications such as nausea and vomiting [1]. Patients suffering from coronary heart disease, stroke or peripheral vascular disease, commonly present for surgery while on anticoagulants (AC) and/or antiplatelet agents (APA). Discontinuation of AC or APA perioperatively may expose patients to cardiac, neurologic or vascular complications. Although these patients may benefit from peripheral nerve blocks, they are often denied this option out of concern for bleeding complications along the needle pathway. In addition, the risk/benefit ratio may be difficult to assess. Complications related to peripheral nerve blocks in patients receiving AC or APA, such as haematoma, active bleeding or nerve compression have been described.

The main objective of this systematic review was to summarise the existing literature on bleeding complications following peripheral nerve blocks in patients receiving AC and/or APA.

## **Method**

A systematic review was performed in accordance with the Cochrane Collaboration recommendations (Cochrane Handbook for Systematic Reviews of Interventions) [2]. The

subject was defined by PICO (Participants, Interventions, Comparisons and Outcomes): patients receiving AC and/or APA, who underwent a peripheral nerve block. The outcome was bleeding.

Databases consulted for this medical bibliography search were : *MEDLINE, Cochrane, Embase, CISMEF (Catalogue et Index des Sites Médicaux de Langue Française), base de données bibliographique en langue française, BDSP (Banque de Données en Santé Publique), SFAR (Société Française d'Anesthésie et de Réanimation), HAS ( Haute Autorité de Santé), ANSM ( Agence Nationale de sécurité du Médicament et des Produits de Santé), google scholar and grey literature and social networks (Facebook, Twitter, ResearchGate...)* .

The initial search was performed between September 2015 and December 2015. An additional search using the same keywords was performed in August 2018, in order to check for any subsequently published articles or reviews.

The protocol was registered with the PROSPERO website, Newcastle UK, under CRD42016032514. (<http://www.crd.york.ac.uk/PROSPERO/>)

MESH keywords were primarily used on Pubmed and Medline, using Boolean's operators AND or NOT :

- MESH with Boolean's operators.

("Anticoagulants"[Mesh] OR "Platelet Aggregation Inhibitors"[Majr] OR "Thrombolytic Therapy"[Mesh] OR "Fibrinolytic Agents"[Mesh]) AND ("Nerve Block"[Majr] OR "Anesthesia, Local"[Mesh]) NOT "Cataract"[Mesh])

OR ("Brachial Plexus Block"[Majr]) AND ("Anticoagulants"[Mesh] OR "Platelet Aggregation Inhibitors"[Majr] OR "Thrombolytic Therapy"[Mesh] OR "Fibrinolytic Agents"[Mesh])

OR ("Cervical Plexus Block"[Majr]) AND ("Anticoagulants"[Mesh] OR "Platelet Aggregation Inhibitors"[Majr] OR "Thrombolytic Therapy"[Mesh] OR "Fibrinolytic Agents"[Mesh])

OR ("Aspirin"[Majr] OR "Heparin"[Majr] OR "Heparin, Low-Molecular-Weight"[Majr] OR "Warfarin"[Mesh] OR "Factor Xa Inhibitors"[Majr]) AND ("Nerve Block"[Majr])

- CISMEF

(anesthésie de conduction.mc[TER\_MSH]) AND ((anticoagulants oraux.sr[TER\_CIS]) OR (NACO.sr[TER\_CIS]) OR antiagrégants plaquettaires.mc[TER\_MSH]) OR ((anticoagulants oraux.sr[TER\_CIS]) OR antiagrégants plaquettaires.mc[TER\_MSH]) AND bloc nerveux.mc[TER\_MSH]

Inclusion criteria were: English, French and Spanish publications related to single or multiple peripheral nerve blocks in patients receiving AC and/or APA.

Exclusions criteria were: studies on neuraxial and eye blocks.

## Results

One hundred and forty publications were reviewed. One hundred and nine were excluded because they were off topic and a further 3 were not in English, leaving 4 consensus statements, 6 original articles and 18 case reports (*figure 1*).

Twenty-four studies were included in this systematic review: 6 prospective or retrospective observational studies [3-8] and 18 case reports [9-26]. All these studies were identified in PubMed.

Characteristics of the studies including title, year of publication, sample size, age, gender and type of treatment (AC and/or APA) are described in tables 1 and 2.

In 4 publications, patients were receiving APA only, in 14 publications AC only, and in 6 studies both AC and APA.

Only studies with grade C level of evidence were identified.

Among the 24 studies included, 9738 peripheral nerve blocks were performed in 5876 patients.

The main results of individual observational studies and case reports are presented in the tables 3 and 4.

In six observational studies, 65 bleeding complications were identified, in a sample of 9688 peripheral nerve blocks performed in 5845 patients. Peripheral nerve block types included: femoral, sciatic, lumbar plexus, cervical, paravertebral, interscalene, supra- and infraclavicular blocks. Peripheral nerve blocks were performed using solely neurostimulation in 2 studies, neurostimulation combined with ultrasound in 1 study, and anatomical landmarks only in 3 studies. In 4 studies (2583 blocks), patients were receiving AC. In 1 study (170 blocks), patients were receiving APA and, in another study, (6935 blocks), patients were receiving both APA and AC. Antiplatelet agents were not stopped before surgery. Anticoagulants were administered either the day of surgery or the following day, for thromboprophylaxis.

Bleeding complications included:

- i) 61 haematomas at the puncture site of femoral catheters occurring on the second postoperative day, without neurological compromise (patients on prophylactic rivaroxaban, commenced the day following surgery),
- ii) 1 local bleeding after lumbar plexus catheter removal without haematoma formation or neurological compromise, treated with compression and vitamin K (patient on therapeutic warfarin, INR =3), and
- iii) 3 minor bleeds at the site of a femoral, sciatic and lumbar plexus catheter insertion (patients on prophylactic rivaroxaban commenced the day following surgery).

Based on these observational studies, the estimated incidence of bleeding complications associated with peripheral nerve blocks in patients treated with AC or APA was 0.67% (0.51%-0.83%). There was no link between these and the nerve localization technique (ultrasound/neurostimulation/anatomical landmarks)

Eighteen case reports were identified, presenting 31 patients (21 males and 10 females) and 50 peripheral nerve blocks. The median age of patients was 65 years (24). Peripheral nerve blocks were performed using ultrasound in 4 cases, neurostimulation in 9 cases, both neurostimulation and ultrasound in 3 cases, anatomical landmarks in 1 case, and fluoroscopy in 1 case. The type and dose (prophylactic or therapeutic) of anti-clotting medication as well as the incidence of bleeding complications are depicted in *figure 2*.

Fifteen bleeding complications were described.

Outcomes were: 1 death, 7 transfusions, 1 embolization and 1 surgical exploration.



The death was secondary to haemorrhagic shock as a result of retro-peritoneal haematoma following a lumbar block performed 3 days after stopping clopidogrel.

No long-term neurological deficit has been identified.

## **Discussion**

This systematic review shows that the incidence of bleeding complications associated with peripheral regional anaesthesia in patients chronically treated with an antiplatelet agent and/or an anticoagulant in the 6 published cohort studies is estimated at 0.67% [CI 95%: 0.51%-0.83%]. The only study in patients treated with antiplatelet agents alone shows no complication with superficial blocks (femoral, sciatic and cervical blocks) [6]. Among 50 patients from case reports, 15 bleeding complications have been described. If we were to include the case reports in the analysis, the incidence would rise to 0.82% [CI 95%: 0.64%-1.0%]. Comparison to patients naive or not exposed to anticoagulant or antiplatelet agents seems difficult since bleeding complications of peripheral regional anaesthesia are also described in patients not treated with anticoagulants or without identifiable haemostatic disease. [27-29]

No case of neuropathy was identified or related to a bleeding complication. In the study of Sites et al, 1.8% of 12668 peripheral nerve blocks were complicated by neuropathy (0.9% at 6 months) and 1.8% by venous or arterial puncture [30]. Among 159 claims related to peripheral regional anaesthesia from the ASA closed claim analysis, 59% were adjudicated as neuropathies [31]. These neuropathies (including transient neuropathies) may be the consequence of bleeding complications such as haematomas causing nerve compression or injuries of the vasa nervorum.

In relation to “deep blocks”, several severe bleeding complications (according to Kozek-Langenecker’s definition) have been published (in this review: paravertebral, lumbar, supra, infra clavicular, intercostal, sciatic, sympathetic, interscalene) [32]. The severity of these complications is explained by different factors: 1) the inability to perform an efficient compression of the anatomical site, 2) the proximity of a large vessel, 3) the absence of a cutaneous haematoma which hinders an early detection of a more severe bleeding complication, 4) the delayed onset of neurologic symptoms following the bleed (lumbar block), 5) the proximity of the spinal cord (paravertebral block).

Regarding “superficial” blocks, the literature is too scarce to draw any practical guidance [33].

Very few studies mentioned the use of ultrasound techniques to guide peripheral regional anaesthesia. Ultrasound techniques decrease but do not eliminate inadvertent vascular puncture since small vessels may not be detected. However, vascular puncture by itself is not necessarily associated with bleeding complications. Stan et al reported 0.2% bleeding complications among 1000 transarterial axillary blocks [33].

Bleeding complications after peripheral regional anaesthesia have been described not only with therapeutic doses of anticoagulants but also with lower “prophylactic” doses. Six case reports with 6 complications in patients treated with low-dose anticoagulants have been published. Two cohort studies described bleeding complications in patients receiving a prophylactic regimen.

This systematic review has several limitations related to the methodology of systematic reviews: 1) no high quality (level of evidence A or B) study has been identified on this subject, 2) cohort studies include small populations, multiple peripheral regional anaesthesia

techniques and different treatment regimens (anticoagulant and /or antiplatelet agents), 3) heterogeneity of outcomes in the studies 4) publication biases: case reports describe more severe complications than the 6 cohort studies, 5 ) multiple anticoagulant regimens (low, versus high doses) and stopping rules, 6) lack of a clear definition of « deep » versus « superficial » blocks. Tables 5 and 6 summarise the conclusions of current guidelines from different working groups and societies regarding the safety of peripheral regional anaesthesia in patients treated with anticoagulants or antiplatelet agents [34-37]. The heterogeneity of these recommendations reflects the difficulty to issue strong recommendations on safety in the absence of consistent literature.

The French Working Group on perioperative haemostasis (GIHP) suggests two categories of peripheral nerve blocks: those with low risk of bleeding complications (such as superficial nerve blocks) and those with high risk of bleeding complications (such as deep nerve blocks):

- the former may be performed without stopping APA, and without stopping dabigatran (if the risk/benefit ratio is favourable and justified)

- the latter may be performed while on aspirin alone (but no other APA) as dictated by a favourable risk/benefit ratio, and are contraindicated while on dabigatran

Blocks must be performed with ultrasound [38] [39]. In ASRA's 2018 guidelines, for the first time, different recommendations are made for superficial and deep blocks. [34] In patients undergoing deep blocks, recommendations regarding neuraxial techniques should be similarly applied, while in superficial blocks, management (performance, catheter maintenance, and catheter removal) should be based on site compressibility, vascularity, and consequences of bleeding.

## Conclusion

This review is unique in examining specifically the bleeding complications in patients on anticoagulants or antiplatelet agents undergoing peripheral nerve blocks. The problem could not be more relevant in an era when antithrombotic treatments are increasingly prescribed. However, despite many case reports, with only a few studies on this subject, it is difficult to draw conclusions or design guidelines. Undoubtedly, a measurable, serious impact has been demonstrated in patients on antithrombotic drugs who received deep blocks. Superficial blocks, despite fewer data, are not devoid of complications either. Thus, erring on the side of caution is recommended when performing peripheral nerve blocks in these patients.

Going forward, large studies and continued publication of case reports are needed to inform future guidelines.

## Bibliography

- [1] Liu SS, Strodtbeck WM, Richman JM, Wu CL. A comparison of regional versus general anesthesia for ambulatory anesthesia: a meta-analysis of randomized controlled trials. *Anesth Analg* 2005;101:1634–42. doi:10.1213/01.ANE.0000180829.70036.4F.
- [2] Cochrane Handbook for Systematic Reviews of Interventions n.d. <http://handbook.cochrane.org/> (accessed February 11, 2016).
- [3] Chelly JE, Schilling D. Thromboprophylaxis and peripheral nerve blocks in patients undergoing joint arthroplasty. *J Arthroplasty* 2008;23:350–4. doi:10.1016/j.arth.2007.05.045.
- [4] Chelly JE, Szczodry DM, Neumann KJ. International normalized ratio and prothrombin time values before the removal of a lumbar plexus catheter in patients receiving warfarin after total hip replacement. *Br J Anaesth* 2008;101:250–4. doi:10.1093/bja/aen132.
- [5] Buckenmaier CC, Shields CH, Auton AA, Evans SL, Croll SM, Bleckner LL, et al. Continuous peripheral nerve block in combat casualties receiving low-molecular weight heparin. *Br J Anaesth* 2006;97:874–7. doi:10.1093/bja/ael269.
- [6] Madi-Jebara S, Rkeiby-Kassabian N, Yazigi A. [Antiplatelet agents and regional anaesthesia: experience in 130 patients]. *Ann Fr Anesthèsie Rèanimation* 2005;24:565. doi:10.1016/j.annfar.2005.03.008.
- [7] Idestrup C, Sawhney M, Nix C, Kiss A. The incidence of hematoma formation in patients with continuous femoral catheters following total knee arthroplasty while receiving rivaroxaban as thromboprophylaxis: an observational study. *Reg Anesth Pain Med* 2014;39:414–417. doi:10.1097/AAP.000000000000127.

- [8] Chelly JE, Metais B, Schilling D, Luke C, Taormina D. Combination of Superficial and Deep Blocks with Rivaroxaban. *Pain Med Malden Mass* 2015;16:2024–30. doi:10.1111/pme.12801.
- [9] Parvaiz MA, Korwar V, McArthur D, Claxton A, Dyer J, Isgar B. Large retroperitoneal haematoma: an unexpected complication of ilioinguinal nerve block for inguinal hernia repair. *Anaesthesia* 2012;67:80–1. doi:10.1111/j.1365-2044.2011.06971.x.
- [10] Bigeleisen PE. Ultrasound-guided infraclavicular block in an anticoagulated and anesthetized patient. *Anesth Analg* 2007;104:1285–7, tables of contents. doi:10.1213/01.ANE.0000181832.09267.08.
- [11] Ben-David B, Joshi R, Chelly JE. Sciatic nerve palsy after total hip arthroplasty in a patient receiving continuous lumbar plexus block. *Anesth Analg* 2003;97:1180–2, table of contents.
- [12] Bickler P, Brandes J, Lee M, Bozic K, Chesbro B, Claassen J. Bleeding complications from femoral and sciatic nerve catheters in patients receiving low molecular weight heparin. *Anesth Analg* 2006;103:1036–7. doi:10.1213/01.ane.0000237230.40246.44.
- [13] Poivert C, Malinovsky J-M. [Thigh haematoma after sciatic nerve block and fondaparinux]. *Ann Fr Anesthésie Réanimation* 2012;31:484–5. doi:10.1016/j.annfar.2011.12.015.
- [14] Ferraro LHC, Tardelli MA, Yamashita AM, Cardone JDB, Kishi JM. Ultrasound-guided femoral and sciatic nerve blocks in an anticoagulated patient. Case reports. *Rev Bras Anesthesiol* 2010;60:422–8. doi:10.1016/S0034-7094(10)70052-0.
- [15] Plunkett AR, Buckenmaier CC. Safety of multiple, simultaneous continuous peripheral nerve block catheters in a patient receiving therapeutic low-molecular-weight heparin. *Pain Med Malden Mass* 2008;9:624–7. doi:10.1111/j.1526-4637.2008.00418.x.
- [16] Khelemsky Y, Rosenblatt MA. Ultrasound-guided supraclavicular block in a patient anticoagulated with argatroban. *Pain Pract Off J World Inst Pain* 2008;8:152. doi:10.1111/j.1533-2500.2008.00184.x.
- [17] Taninishi H, Morita K. Ultrasound-guided peripheral nerve blocks for a patient receiving four kinds of anticoagulant and antiplatelet drugs: a case report. *J Anesth* 2011;25:318–20. doi:10.1007/s00540-011-1093-8.
- [18] Dauri M, Faria S, Celidonio L, Tarantino U, Fabbi E, Sabato AF. Retroperitoneal haematoma in a patient with continuous psoas compartment block and enoxaparin administration for total knee replacement. *Br J Anaesth* 2009;103:309–10. doi:10.1093/bja/aep189.
- [19] Aveline C, Bonnet F. Delayed retroperitoneal haematoma after failed lumbar plexus block. *Br J Anaesth* 2004;93:589–91. doi:10.1093/bja/ae242.
- [20] Klein SM, D’Ercole F, Greengrass RA, Warner DS. Enoxaparin associated with psoas hematoma and lumbar plexopathy after lumbar plexus block. *Anesthesiology* 1997;87:1576–9.
- [21] Weller RS, Gerancher JC, Crews JC, Wade KL. Extensive retroperitoneal hematoma without neurologic deficit in two patients who underwent lumbar plexus block and were later anticoagulated. *Anesthesiology* 2003;98:581–5.
- [22] Maier C, Gleim M, Weiss T, Stachetzki U, Nicolas V, Zenz M. Severe bleeding following lumbar sympathetic blockade in two patients under medication with irreversible platelet aggregation inhibitors. *Anesthesiology* 2002;97:740–3.
- [23] Nielsen CH. Bleeding after intercostal nerve block in a patient anticoagulated with heparin. *Anesthesiology* 1989;71:162–4.
- [24] Mani M, Ramamurthy N, Rao TL, Winnie AP, Collins VJ. An unusual complication of brachial plexus block and heparin therapy. *Anesthesiology* 1978;48:213–4.
- [25] Tantry TP, Kadam D, Shetty P, Bhandary S. Combined femoral and sciatic nerve blocks for lower limb anaesthesia in anticoagulated patients with severe cardiac valvular lesions. *Indian J Anaesth* 2010;54:235–8. doi:10.4103/0019-5049.65372.
- [26] Martins LES, Ferraro LHC, Takeda A, Munechika M, Tardelli MA. Ultrasound-guided peripheral nerve blocks in anticoagulated patients - case series. *Braz J Anesthesiol Elsevier* 2017;67:100–6. doi:10.1016/j.bjane.2015.06.005.

- [27] Aida S, Takahashi H, Shimoji K. Renal subcapsular hematoma after lumbar plexus block. *Anesthesiology* 1996;84:452–5.
- [28] Ben-David B, Stahl S. Axillary block complicated by hematoma and radial nerve injury. *Reg Anesth Pain Med* 1999;24:264–6.
- [29] Cockings E. Axillary block complicated by hematoma and radial nerve injury. *Reg Anesth Pain Med* 2000;25:103.
- [30] Sites BD, Taenzer AH, Herrick MD, Gilloon C, Antonakakis J, Richins J, et al. Incidence of Local Anesthetic Systemic Toxicity and Postoperative Neurologic Symptoms Associated With 12,668 Ultrasound-Guided Nerve Blocks: An Analysis From a Prospective Clinical Registry. *Reg Anesth Pain Med* 2012;37:478–82. doi:10.1097/AAP.0b013e31825cb3d6.
- [31] Lee LA, Posner KL, Cheney FW, Caplan RA, Domino KB. Complications associated with eye blocks and peripheral nerve blocks: an american society of anesthesiologists closed claims analysis. *Reg Anesth Pain Med* 2008;33:416–22. doi:10.1016/j.rapm.2008.01.016.
- [32] Kozek S. [Modern anaesthesiological techniques and anticoagulation]. *Hämostaseologie* 2006;26:S41-51.
- [33] Stan TC, Krantz MA, Solomon DL, Poulos JG, Chaouki K. The incidence of neurovascular complications following axillary brachial plexus block using a transarterial approach. A prospective study of 1,000 consecutive patients. *Reg Anesth* 1995;20:486–92.
- [34] Horlocker TT, Vandermeulen E, Kopp SL, Gogarten W, Leffert LR, Benzon HT. Regional Anesthesia in the Patient Receiving Antithrombotic or Thrombolytic Therapy: American Society of Regional Anesthesia and Pain Medicine Evidence-Based Guidelines (Fourth Edition). *Reg Anesth Pain Med* 2018;43:263–309. doi:10.1097/AAP.0000000000000763.
- [35] Gogarten W, Vandermeulen E, Van Aken H, Kozek S, Llau JV, Samama CM, et al. Regional anaesthesia and antithrombotic agents: recommendations of the European Society of Anaesthesiology. *Eur J Anaesthesiol* 2010;27:999–1015. doi:10.1097/EJA.0b013e32833f6f6f.
- [36] 2a\_AFAR\_Prise-en-charge-de-la-douleur-postoperatoire-chez-ladulte-et-lenfant.pdf n.d.
- [37] Chelly JE, Clark LD, Gebhard RE, Raw RM, Atchabahian A. Consensus of the Orthopedic Anesthesia, Pain, and Rehabilitation Society on the use of peripheral nerve blocks in patients receiving thromboprophylaxis. *J Clin Anesth* 2014;26:69–74. doi:10.1016/j.jclinane.2013.09.012.
- [38] Godier A, Fontana P, Motte S, Steib A, Bonhomme F, Schlumberger S, et al. Management of antiplatelet therapy in patients undergoing elective invasive procedures. Proposals from the French Working Group on perioperative haemostasis (GIHP) and the French Study Group on thrombosis and haemostasis (GFHT). In collaboration with the French Society for Anaesthesia and Intensive Care Medicine (SFAR). *Anaesth Crit Care Pain Med* 2018;37:379–89. doi:10.1016/j.accpm.2017.12.012.
- [39] Albaladejo P, Pernod G, Godier A, de Maistre E, Rosencher N, Mas JL, et al. Management of bleeding and emergency invasive procedures in patients on dabigatran: Updated guidelines from the French Working Group on Perioperative Haemostasis (GIHP) - September 2016. *Anaesth Crit Care Pain Med* 2018;37:391–9. doi:10.1016/j.accpm.2018.04.009.

Figure 1: Flow chart

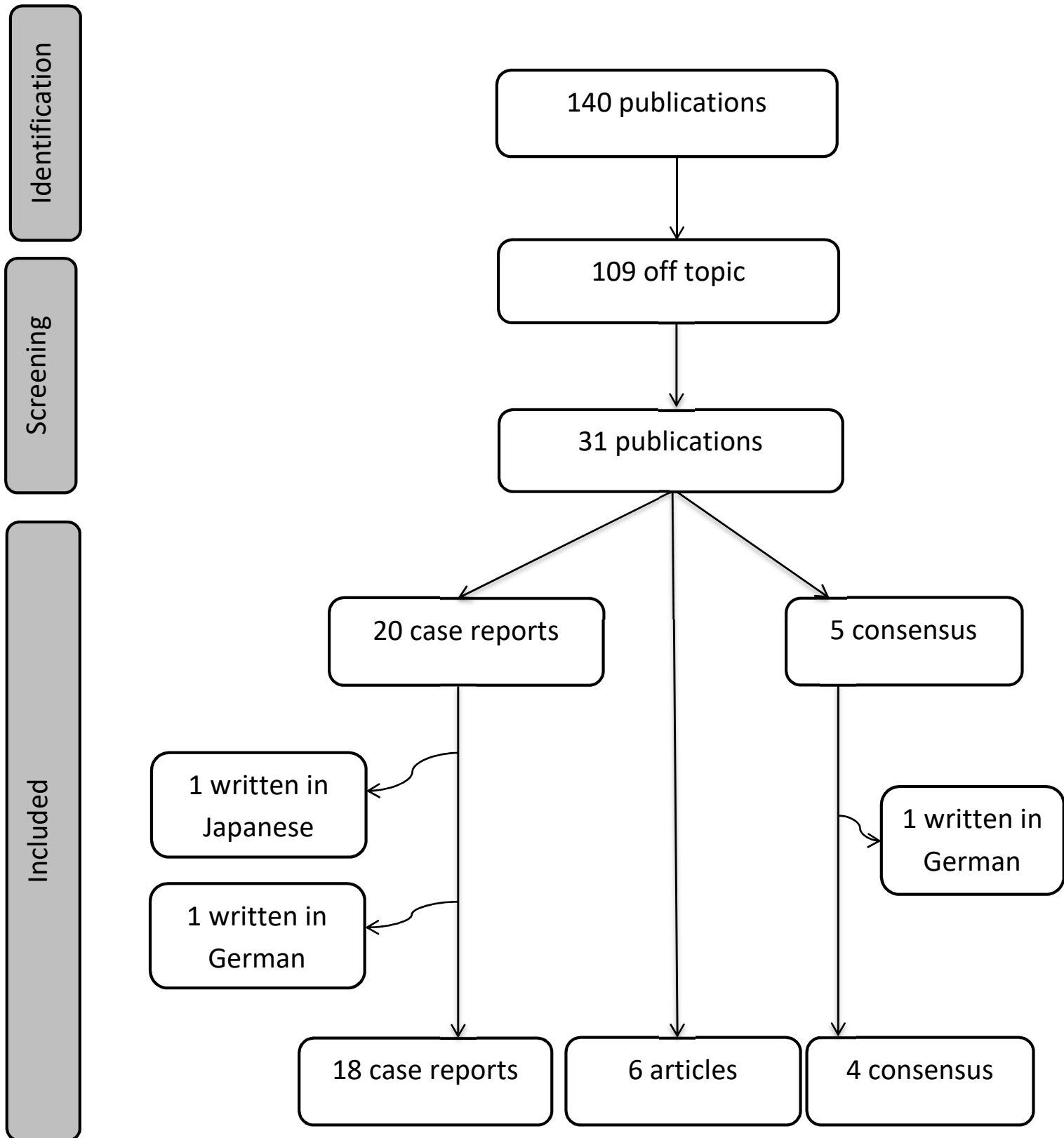


Figure 2: Type and dose of anti-clotting drugs, and incidence of bleeding complications in 31 patients identified in 18 case reports

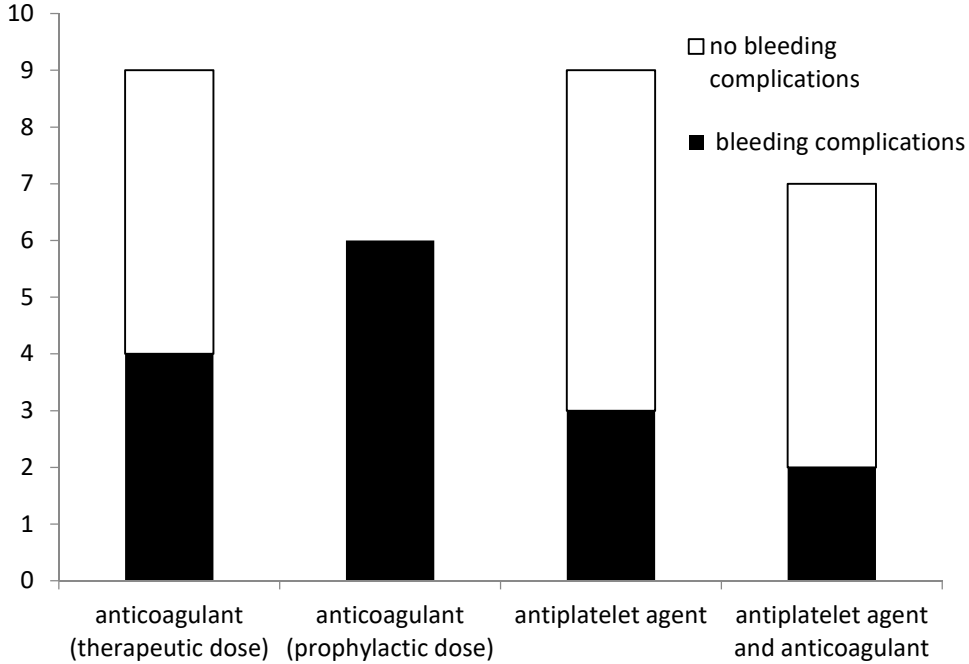




Table 1: Description of the observational prospective single center studies (Grade C evidence)

<b>Title</b>	<b>Year of publication</b>	<b>Journal</b>	<b>Population (n)</b>	<b>Age (mean SD), gender</b>	<b>Treatment</b>	<b>Number of blocks</b>	<b>Study period</b>
Antiplatelet agents and regional anaesthesia: experience in 130 patients [6]	2006	Annales françaises d'Anesthésie et de Réanimation	130	67 years, 32 females, 98 males	aspirin, clopidogrel	170	January to June 2004
Thromboprophylaxis and peripheral nerve blocks in patients undergoing joint arthroplasty [3]	2008	The Journal of Arthroplasty	3 588	not reported	warfarin, fondaparinux, dalteparin, enoxaparin, aspirin	6 935	July 2002 to November 2005
International normalized ratio and prothrombin time values before the removal of lumbar plexus catheter in patients receiving warfarin after total hip replacement [4]	2008	British Journal of Anaesthesia	670	63 years (median) (18-100); 360 females, 302 males	warfarin	670	August 2002 to June 2007
The incidence of hematoma formation in patients with continuous femoral catheters following total knee arthroplasty while receiving rivaroxaban as thromboprophylaxis [7]	2014	Regional Anesthesia and Pain Medicine	504	67 years; 323 females, 181 males	rivaroxaban	504	January 2009 to May 2010
Continuous peripheral nerve block in combat casualties receiving low molecular weight heparin [5]	2014	British Journal of Anaesthesia	187	25 years (median)(19-58), 177males, 10 females	enoxaparin	305	March 2003 to April 2005
Combination of superficial and deep blocks with rivaroxaban [8]	2015	Pain Medicine	766	65 years; 483 females, 283 males	rivaroxaban	1 104	October 2012 to October 2014

Table 2: Description of the case reports (Grade C evidence)

<b>Title</b>	<b>Journal</b>	<b>Population (n)</b>	<b>Age (years), gender</b>	<b>Treatment</b>	<b>Number of blocks</b>	<b>Study period</b>
An unusual complication of brachial plexus block and heparin therapy [24]	Anesthesiology	1	33, male	heparin	1	1977
Bleeding after intercostal nerve block in a patient anticoagulated with heparin [23]	Anesthesiology	1	80, male	heparin	1	1989
Enoxaparin associated with psoas hematoma and lumbar plexopathy after lumbar plexus block [20]	Anesthesiology	286 lumbar plexus blocks in 1 year	67, female	aspirin and enoxaparin	1	1997
Severe bleeding following lumbar sympathetic blockade in two patients under medication with irreversible platelet aggregation inhibitors [22]	Anesthesiology	2000 lumbar sympathetic blocks since 1985	71, male	ticlopidine	1	2001
			79, female	clopidogrel	1	
Extensive retroperitoneal hematoma without neurological deficit in two patients who underwent lumbar plexus blocks and were later anticoagulated [21]	Anesthesiology	2	85, female	enoxaparin	2	2002
			65, male	heparin and warfarin	2	
Sciatic nerve palsy after total hip arthroplasty in patient receiving continuous lumbar plexus block [11]	Anesthesia Analgesia	1	30, male	enoxaparin	1	2003
Delayed retroperitoneal haematoma after failed lumbar plexus block [19]	British Journal of Anaesthesia	1	72, female	phenylindanedione and enoxaparin	1	2004

<b>Title</b>	<b>Journal</b>	<b>Population (n)</b>	<b>Age (years), gender</b>	<b>Treatment</b>	<b>Number of blocks</b>	<b>Study period</b>
Ultrasound guided infraclavicular block in an anticoagulated and anesthetized patient [10]	Anesthesia Analgesia	1	29, male	heparin	1	2005
Bleeding complications from femoral and sciatic nerve catheters in patients receiving low molecular weight heparin [12]	Anesthesia Analgesia	3	49, male	enoxaparin	2	2006
			78, female	enoxaparin	2	
			48, female	enoxaparin	2	
Safety of multiple, simultaneous continuous peripheral nerve block catheters in a patient receiving therapeutic low molecular weight heparin [15]	Pain Medicine	1	32, male	enoxaparin	3	2008
Ultrasound guided supraclavicular block in a patient anticoagulated with argatroban [16]	Pain Practice	1	59, male	argatroban	1	2008
Ultrasound guided femoral and sciatic nerve blocks in an anticoagulated patient [14]	Revista Brasileira de Anestesiologia	2	65, male	aspirin and clopidogrel	2	2010
			71, male	aspirin and warfarin	2	
Ultrasound guided peripheral nerve blocks for a patient receiving four kinds of anticoagulant and antiplatelet drugs: a case report [17]	Journal of Anesthesia	1	64, male	heparin, aspirin and ticlopidine	2	2010
Thigh haematoma after sciatic nerve block and fondaparinux [13]	Annales Françaises d'Anesthésie et de Réanimation	1	42, female	fondaparinux	1	2011

<b>Title</b>	<b>Journal</b>	<b>Population (n)</b>	<b>Age (years), gender</b>	<b>Treatment</b>	<b>Number of blocks</b>	<b>Study period</b>
Large retroperitoneal haematoma: an unexpected complication of ilioinguinal nerve block for inguinal hernia repair [9]	Anaesthesia	1	71, male	aspirin and dipyridamole	1	2012
Retroperitoneal haematoma in a patient with continuous psoas compartment block and enoxaparin administration for total knee replacement [18]	British Journal of Anaesthesia	1	77, male	enoxaparin	1	2015
Combined femoral and sciatic nerve blocks for lower limb anaesthesia in anticoagulated patients with severe cardiac valvular lesions [25]	Indian Journal of Anaesthesia	2	42, female	warfarin, heparin	2	2010
			73, male	aspirin and clopidogrel	2	
Ultrasound-guided peripheral nerve blocks in anticoagulated patients-case series [26]	Revista Brasileira de Anestesiologia	8	63, female	aspirin, clopidogrel and heparin	2	2015
			57, male	aspirin and clopidogrel	2	
			74, male	aspirin and clopidogrel	2	
			32, male	enoxaparin	2	
			73, female	aspirin and heparin	1	
			71, male	clopidogrel	2	
			65, male	aspirin+clopidogrel	2	
			71, male	aspirin+warfarin (INR=5,9)	2	

Table 3: Main results of the observational studies

Ref	type of block (n)	ultrasound guidance/nerve stimulation	anticoagulant/antiplatelet agents: dose, commencement	main objective	development of neuropathy	complication and its occurrence	treatment of complications
[6]	<b>superficial:</b> cervical (90); sciatic (40) and femoral (40)	nerve stimulation	aspirin or clopidogrel until surgery	to evaluate the haemorrhagic risk when patients under antiplatelet agent have cervical block or sciatic and femoral block	not reported	no perineural haematoma	-
[3]	<b>deep:</b> lumbar plexus: continuous (1804), single shot (4); <b>superficial:</b> femoral: continuous (1790); sciatic: continuous (1731), single shot (1607)		<b>therapeutic:</b> aspirin 325 mg day 0; dalteparin 5000 Ui day 1; enoxaparin 30 mg day 1; fondaparinux 2.5mg day 1; warfarin 5 and 7.5 mg day 0 and 1;	to assess the risk of perineural bleeding associated with the use of peripheral nerve blocks in patients undergoing major orthopaedic surgery and requiring post-operative thromboprophylaxis	2 cases of delay in motor function recovery	no perineural haematoma	-
[4]	<b>deep:</b> continuous lumbar plexus (removal day 2) (670)		<b>therapeutic:</b> warfarin (2.5 to 10 mg depending on patients);	to establish the coagulation status using INR and PT at the time of removal of lumbar plexus perineural catheters in patients receiving warfarin after total hip replacement	1 femoral nerve injury, resolved within 7 months	1 case of local bleeding without haematoma formation or neurological compromise (p=0.15% [-0.14%-0.44%])	direct pressure on the site after removal and vitamin K

Ref	type of block (n)	ultrasound guidance/nerve stimulation	anticoagulant/antiplatelet: dose, commencement	main objective	development of neuropathy	complications and time of occurrence	treatment of complications
[7]	<b>superficial:</b> continuous femoral	US and nerve stimulation	<b>prophylactic:</b> rivaroxaban 10 mg/day, day1; injection 20h before catheter removal and 4h after	to investigate the incidence of haematoma formation, causing neurovascular compromise, for patients with femoral catheters while taking oral anticoagulant rivaroxaban	Day 3: 3 decreased sensory and motor function (spontaneous resolution)	no haematoma with neurovascular compromise, 61 ecchymosis (p=12.1% [ 9.26%-14.95%] )	-
[5]	<b>deep and superficial:</b> lumbar (88); sciatic (113); supraclavicular (31); infraclavicular (13); interscalene (7); femoral (7); paravertebral (4)	nerve stimulation	<b>prophylactic:</b> enoxaparin 30 mg injection 21h before catheter insertion and 12h after; and injection 11h before catheter removal and 8h after	to describe continuous peripheral nerve block in combat trauma patient treated with LMWH	not reported	no bleeding complication; others complications : 2 malfunction, 2 infections and 3 dislocations	-
[8]	<b>deep and superficial:</b> continuous lumbar plexus (200); continuous femoral (509), continuous sciatic (320)	-	<b>prophylactic:</b> rivaroxaban 10 mg/day, day 1	to evaluate the bleeding from the combination of either a single or a continuous deep, superficial, and plexus block and the use of rivaroxaban for thromboprophylaxis following joint arthroplasty	not reported	3 minor bleeds at the site of perineural catheter insertion	-

Table 4: Main results from the 18 case reports

Ref	type of block (n)	ultrasound guidance/nerve stimulation	blood aspiration	anticoagulant/antiaggregant: dose and introduction	development of neuropathy	complication and its occurrence	treatment of complications
[24]	<b>deep:</b> supraclavicular brachial plexus block	no	no	<b>therapeutic:</b> heparin 5000uix4/day after surgery	-	hemothorax (Day 3)	chest tube
[23]	<b>deep:</b> intercostal nerve block T7 to T11, bilaterally	no	not reported	<b>therapeutic:</b> heparin 5000UIx3/day	-	large chest haematoma (Day 3)	transfusion 8 units of red cell concentrate
[20]	<b>deep:</b> lumbar plexus	nerve stimulation	no	<b>therapeutic:</b> aspirin 325mg and enoxaparine 30mgx2/day (stopped 19h before surgery and recommenced 4h30 after)	4 months: no sensory and motor deficit	large retroperitoneal hematoma (Day 9: unable to move her leg)	no surgery
[22]	<b>deep:</b> lumbar sympathetic (2)	radiographic control	one with vascular puncture	ticlopidine 500mg/day	not reported	large retroperitoneal hematoma (Day 7 first block and Day 2 second block)	transfusion
	<b>deep:</b> lumbar sympathetic (2)	radiographic control	one with vascular puncture	clopidogrel 75mg/day, stopped 3 days before the blockade	not reported	large retroperitoneal haematoma and death (12 h)	-
[21]	<b>deep and superficial:</b> sciatic and continuous lumbar plexus block	nerve stimulation	no	<b>prophylactic:</b> enoxaparin 30mgx2/day day 2 (injection 1h40 before catheter removal and 10h after)	no neurologic deficit	extensive retroperitoneal hematoma (pain in flank)	no surgery, transfusion of 4 units of concentrated red blood cells

	<b>deep and superficial:</b> sciatic and continuous lumbar plexus block	nerve stimulation	no	<b>therapeutic:</b> heparin 1200UI/hour (8h after block) and coumadine 5mg/day - day 1	not reported	moderate sized retroperitoneal haematoma (Day 4: pain in flank)	no surgery, transfusion of 2 units of concentrated red blood cells, vitamin K 5mg
[11]	<b>deep:</b> continuous lumbar	nerve stimulation	no	<b>prophylactic:</b> enoxaparin 25 mg day 1	decreased sensory and motor function, resolute after evacuation of hematoma	haematoma in the hip with compression of sciatic nerve and palsy (Day 2)	surgery for evacuation
[19]	<b>Deep:</b> lumbar plexus (failed)	nerve stimulation	not reported	<b>Therapeutic:</b> phenylindanedione (stopped 5 days before surgery and recommenced day 3) and enoxaparin 60 mgx2 (stopped 24h before surgery and recommenced 40 mg/day 14h after surgery and 60 mg/day day 2)	Day 45: no deficit	large retroperitoneal hematoma (Day 17)	no surgery, transfusion of 3 units of concentrated red blood cells and vitamin K 5mg
[10]	<b>deep:</b> continuous infraclavicular	US guidance	not reported	<b>therapeutic:</b> heparin 5000ui and 600UI/hour TCA: 203	no neuropathy	no complications	-
[12]	<b>superficial:</b> continuous femoral and sciatic	nerve stimulation	not reported	<b>prophylactic:</b> enoxaparin 40mg/day - day 2 injection 3h before removal	no neurologic deficit	ecchymoses femoral and sciatic after removal (Day 4)	no specific treatment
		nerve stimulation	not reported		Day 5: no neurologic deficit	ecchymose sciatic (day 2)	no specific treatment



		not reported	not reported	<b>prophylactic:</b> enoxaparin 40mg/day 1	not referred	bleeding from the femoral catheter site without haematoma (d+2)	no specific treatment
[15]	<b>superficial:</b> continuous sciatic bilateral and femoral	nerve stimulation	not reported	<b>therapeutic:</b> enoxaparin 100 mgx2 (day injection 24h before catheter insertion)	no neurologic deficit	no haematoma	-
[16]	<b>deep:</b> supraclavicular	ultrasound guidance	not reported	<b>therapeutic:</b> argatroban 0.25 µg/kg/min (INR: 2.7)	Day 1: no neurologic deficit	no haematoma	-
[14]	<b>superficial and deep:</b> femoral and infragluteal sciatic	ultrasound guidance and nerve stimulation	not reported	<b>therapeutic:</b> aspirin 100 mg/day and clopidogrel 75mg/day	no neurologic deficit	no haematoma	-
	<b>superficial and deep:</b> femoral and infragluteal sciatic i	ultrasound guidance and nerve stimulation	not reported	<b>therapeutic:</b> aspirin 100 mg/day and warfarin 5mg/day (INR: 5.84)	no neurologic deficit	no hematoma	-
[17]	<b>superficial:</b> sciatic popliteal and femoral	ultrasound guidance	not reported	<b>therapeutic:</b> heparin 15000 Ui/day (stopped just in the operation room), aspirin 100 mg/day (continued), ticlopidine 200 mg/day (stopped day before surgery)	not reported	no haematoma	-
[13]	<b>deep:</b> anterior block sciatic (a lot of punctures)	nerve stimulation	not reported	<b>prophylactic:</b> fondaparinux 2.5 mg day 1	no neurologic deficit	Hip haematoma (6x9x3cm) (Day 4)	no specific treatment

[9]	<b>superficial:</b> ilioinguinal/iliohypogastric	no	no	aspirin (stopped 1 week before surgery) and dipyridamole	not reported	large right retroperitoneal haematoma measuring 22x10x7cm (Day 9: right flank pain)	blood transfusion, embolization
[18]	<b>deep:</b> continuous psoas compartment block	nerve stimulation	no	<b>therapeutic:</b> enoxaparin 4000 UIx2/day (first dose 10h after catheter placement, injection 12h before catheter removal and 3h after)	no sensorimotor deficit	haematoma of psoas muscle 12*15cm (D+4: pain in iliaca fossa)	no surgery, transfusion of 4 units of concentrate red blood cells
[25]	<b>superficial:</b> femoral and sciatic	nerve stimulation	not reported	<b>therapeutic:</b> warfarin (INR: 1.6) and heparin during surgery (5000+2500UI)	not reported	no haematoma	-
	<b>superficial:</b> femoral and sciatic	nerve stimulation	not reported	aspirin 75mg and clopidogrel 75mg	not reported	no haematoma	-
[26]	<b>superficial:</b> femoral and sciatic	ultrasound guidance and nerve stimulation	not reported	aspirin 100 mg, clopidogrel 75 mg and heparin 5000 ui x3/day	no neurologic deficit	no haematoma	-
			not reported	aspirin 100 mg and clopidogrel 75 mg	no neurologic deficit	no haematoma	-
			not reported	aspirin 100 mg and clopidogrel 75mg	no neurologic deficit	no haematoma	-
			not reported	enoxaparin 60 mg x2/day	no neurologic deficit	no haematoma	-
	<b>deep:</b> interscalene brachial plexus	ultrasound guidance	not reported	aspirin 100 mg and heparin in continuous infusion pump	no neurologic deficit	no haematoma	-

	<b>superficial:</b> femoral and sciatic	ultrasound guidance	not reported	clopidogrel 75 mg	no neurologic deficit	no haematoma	-
ultrasound guidance and nerve stimulation		not reported	aspirin 100 mg, clopidogrel 75 mg and INR=3.4	no neurologic deficit	no haematoma	-	
ultrasound guidance		not reported	aspirin 100 mg and warfarin INR=5.8	no neurologic deficit	no haematoma	-	

Table 5: Conclusions of the current guidelines

Author/group	Years	Argument	Conclusion
Orthopedic anesthesia, pain and rehabilitation society (OAPRS) (Chelly, Clark...)	2011	only 5 case reports of major bleeding between 1997 and 2012 with the combination of peripheral nerve block and thromboprophylaxis. in 670 and 316 cases receiving warfarin for thromboprophylaxis, lumbar plexus catheter were removed with an INR of up to respectively 3.9 and 4	no evidence suggesting an increased risk of major bleeding, including retroperitoneal hematoma, with the combination of thromboprophylaxis and superficial or deep peripheral nerve blocks
American Society of Regional Anesthesia and Pain Medicine (ASRA), fourth edition	2010	A series of 32 patients with bleeding complications after peripheral or plexus block: 14 without anticoagulation (6 serious cases) and 18 with Anticoagulation (15 serious cases)	For patients undergoing deep plexus, they suggest that recommendations regarding neuraxial techniques be similarly applied, For patients undergoing peripheral techniques, they suggest management (performance, catheter maintenance, and catheter removal) based on site compressibility, vascularity, and consequences of bleeding (difference between deep and superficial is a new recommendation)
European Society of Regional Anesthesia (ESRA)	2010		Superficial nerve blocks (like axillary plexus block, femoral nerve block or distal sciatic nerve block) may be performed in the presence of aspirin or anticoagulants. However, whenever possible, time intervals between LMWH administration and catheter insertion or withdrawal that apply to neuraxial blocks should be followed. Lumbar plexus and paravertebral block merit the same recommendations that apply to neuraxial blockade.
Annales françaises d'Anesthésie de de Réanimation	2003		Haematoma in patient with anticoagulant/antiplatelet treatment is exceptional. Risk could be more significant with therapeutic anticoagulation or with deep block.

Table 6: Detailed current drug-related guidelines for neuraxial blockade

Author/group	Antiplatelet medications	Unfractionned intravenous heparin	Unfractionned subcutaneous heparin	Low molecular weight heparin	Warfarin	Fondaparinux	Direct oral anticoagulant
American Society of Regional Anesthesia and Pain Medicine (ASRA), fourth edition	acetylsalicylic acid no contraindication, ticlopidine 10 day, clopidogrel 5 to 7 day, GP IIb/IIIa inhibitor 48h	stop heparin 4-6h before puncture or catheter removal and reintroduction 1h after	prophylaxis: stop 12h before puncture or catheter removal and reintroduction 4h after, therapeutic: stop 24h before puncture or catheter removal and reintroduction 4h after	prophylaxis: stop 12h before puncture or catheter removal and reintroduction 12h after, therapeutic: stop 24h before puncture or catheter removal and reintroduction 24h after	normal INR for puncture and INR $\leq$ 1.5 for removal catheter		ribaroxaban: stop 72h before, dabigatran: stop 72h before
European Society of Regional Anesthesia (ESRA)	acetylsalicylic acid no contraindication, ticlopidine 10 days, prasugrel 10 days, ticagrelor 5 days	stop heparin 4-6h before puncture or catheter removal and reintroduction 1h after	stop heparin 8-12h before puncture or catheter removal and reintroduction 1h after	prophylaxis: stop 12h before puncture or catheter removal and reintroduction 4h after, therapeutic: stop 24h before puncture or catheter removal and reintroduction 4h after	INR<1.4	stop 36-42h before, reintroduction on 6-12h after	rivaroxaban (prophylaxis) stop 22-26 h, reintroduction 4-6h apixaban (prophylaxis): stop 26-30h, reintroduction 4-6h dabigatran (prophylaxis): stop 34h, reintroduction 6h